

Dr. Raymond VanLienden, DVM  
**Animal Clinic of Clifton**

12702 Chapel Rd., Clifton, VA 20124

Phone: (703) 802-0490

<http://www.pethealthcare.net>

---

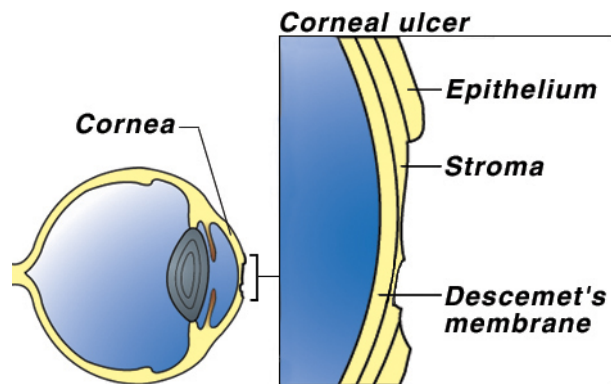
## CORNEAL ULCERS

### *What is a corneal ulcer?*

The cornea is the transparent, shiny membrane which makes up the front of the eyeball. Think of it as a clear window. To understand a corneal ulcer, you must first understand how the cornea is constructed.

The cornea is comprised of three layers. The most superficial layer is the *epithelium*. This layer is comprised of several very thin layers of cells. Think of it in terms of the many layers of an onion skin. Below the epithelium is the *stroma*, and the deepest layer is *Descemet's membrane*. Because all of these layers of the cornea are clear, it is not possible to see them without special stains which color particular cells and highlight them when looked at with an ophthalmoscope.

Erosion of a few layers of the epithelium is called a *corneal erosion* or *corneal abrasion*. A *corneal ulcer* is an erosion through the entire epithelium and into the stroma. If the erosion goes through the epithelium and stroma to the level of Descemet's membrane, a *descemetocoele* exists. This is a serious condition. If Descemet's membrane ruptures, the liquid inside the eyeball leaks out, the eye collapses and irreparable damage can occur.



### *How does a corneal ulcer occur?*

There are several causes of corneal ulcers in dogs. The most common is trauma. An ulcer may result from blunt trauma, such as a dog rubbing its eye on the carpet, or due to a laceration, such as a cat scratch. Another common cause is chemical burn of the cornea. This may happen when irritating shampoo gets in the eye.

Less common causes of corneal ulcers include bacterial infections, viral infections, and other diseases. These may originate in the eye or develop secondary to disease elsewhere in the body. Examples of other diseases include: Epithelial Dystrophy (a weakening of the cornea which can be inherited in breeds such as the Boxer); drying of the cornea due to abnormal tear production, called Keratoconjunctivitis Sicca (KCS or “dye eye”); and diseases of the endocrine system such as diabetes mellitus, Cushing's Disease (hyperadrenocorticism), and hypothyroidism.

### *How does a corneal ulcer affect my dog?*

A corneal ulcer is very painful. Most dogs rub the affected eye with a foot or on the carpet in an attempt to relieve this intense pain. To protect the eye, they keep the lids tightly closed. Occasionally, there will be a discharge that collects in the corner of the eye or runs down the face.

### ***How is a corneal ulcer diagnosed?***

Superficial corneal abrasions are usually not visible. They can be visualized with the use of special stains such as fluorescein. A drop of this stain is placed on the cornea. The dye will adhere to an area of ulceration and is easily seen using special ophthalmic lights. This is the most common eye test performed and may be the only test needed if the ulcer is acute and very superficial. If the ulcerated area is chronic or very deep, samples are taken for culture and cell study prior to applying the stain or other medication.

### ***How is a corneal ulcer treated?***

Treatment depends on whether there is a corneal abrasion, corneal ulcer, or descemetocele present.

Corneal abrasions generally heal within 3-5 days. Medication is used to prevent bacterial infections (antibiotic ophthalmic drops or ointment) and to relieve spasm and pain (atropine ophthalmic drops or ointment). Antibiotic drops are only effective for a few minutes so they must be applied frequently; ointments last a bit longer but still require application every few hours. It is suggested that an antibiotic preparation be instilled in the eye every 4-8 hours. On the other hand, the atropine lasts many hours so this drug is used every 12 to 24 hours.



If a corneal ulcer or descemetocele is present, measures must be taken to protect the eye and to promote healing. Since dogs do not wear eye patches well, surgery is often used to protect the injury and allow for normal healing. Other surgical procedures include

removal of dead or poorly healing cornea, corneal grafts and more. There are several surgical techniques available. Your veterinarian will choose the best surgery to ensure rapid healing for your pet.

### ***Can a corneal abrasion become a corneal ulcer?***

After 2-3 days of treatment, your dog should be re-examined to determine if proper healing is occurring. If not, surgery may be recommended for your pet's condition.

### ***Are there any side-effects from the eye medications?***

Occasionally a dog will be allergic to an ophthalmic antibiotic. If your dog seems to be in more pain after the medication is used, discontinue it and contact your veterinarian immediately.

A corneal ulcer is extremely painful so the eye is kept tightly shut. Atropine relieves the pain but also dilates the pupil widely. Therefore, the eye is very sensitive to light and many dogs will squint or close the eye when exposed to bright light.

The effect of atropine may last for several days after the drug is discontinued. Do not be alarmed if the pupil stays dilated for several days.

***My dog began to drool excessively and paw at its mouth after I administered the eye medications. Is that a reaction?***

No. The tear ducts carry tears from the eyes to the back of the throat. The eye medications may go through the tear ducts and eventually get to the throat where they are tasted. Atropine has a very bitter taste, which may cause drooling, and pawing at the mouth. You are seeing your dog's response to a bad taste, not a drug reaction.

***Since a corneal ulcer is painful, can I apply a topical anesthetic to the cornea?***

A topical anesthetic is often used to numb the cornea so the diagnostic tests may be performed. However, these drugs often delay healing and should be used with discretion.

***How do I know when to discontinue medication?***

The best way to tell that the cornea has healed is to repeat the fluorescein stain test. This will be performed by your veterinarian 5-7 days after treatment has begun.

***There appear to be some red streaks near the ulcer. Is that normal?***

The normal cornea has no blood vessels in it. However, when a corneal ulcer or descemetocele occurs, the body tries to heal by growing new blood vessels through a process called *neovascularization*. The new vessels begin at the sclera (the white part of the eye) and cross the cornea to the ulcer.

Neovascularization is a good response because it indicates healing. However, after the ulcer is healed, these vessels remain in the cornea. They are not painful, but they do obstruct vision. Therefore, it is desirable to remove them. This is done with the use of ophthalmic drops or ointment containing a corticosteroid, which may be used for a few days to several weeks, depending on how much neovascularization is present.

It is important that steroids are not used in the eye too soon because they will stop the healing process and may cause complications. Therefore, the fluorescein dye test should be performed before beginning this type of medication. If steroids are used and the eye becomes painful again, discontinue the steroids and contact your veterinarian.